

A Case Series Assessing the Efficacy of ActivHeal® Hydrogel

CAROLYNNE SINCLAIR, TISSUE VIABILITY NURSE, COUNTESS OF CHESTER NHS FOUNDATION TRUST, CHESTER.

Introduction

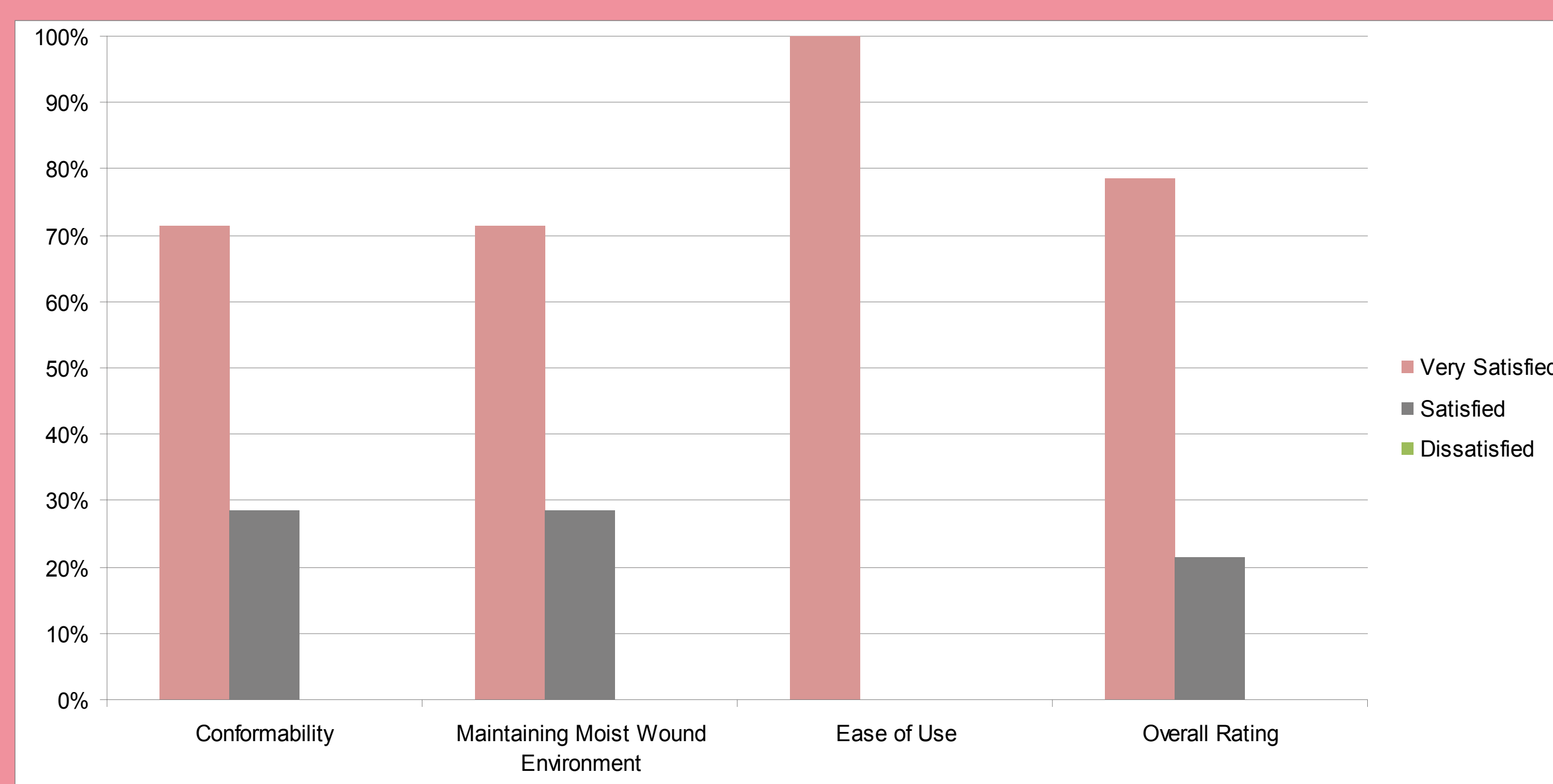
There are a wide range of wound dressings available in the market place. All of these dressings having different evidence and performance characteristics. We underwent a case series to analyse the efficacy of current hydrogel dressing available on the market. ActivHeal® Hydrogel is available in a 15g tube, and is indicated for nil to low exuding wounds and wounds which are either necrotic or sloughy. As ActivHeal® Hydrogel is significantly less expensive than other leading hydrogels on the market we wanted to investigate if its performance was comparable as this would offer cost savings without compromising patient care. The aim was to provide information on the clinical performance of ActivHeal® Hydrogel so that informed decisions could be made about the product.

Method

ActivHeal® Hydrogel was tried on 10 patients. The patients were included on the basis of them having wounds that were suited to ActivHeal® Hydrogel in accordance with the indication and contra indications in the 'instructions for use' insert leaflet, and were treated according to the trusts wound care protocol. The dressings were assessed for their ability to debride and support autolysis, ability to stay in place, ability to maintain a moist wound environment and patient comfort whilst *in situ*. The dressings were applied and changed as required by the patients needs or as dictated by the level of exudate. At least four dressing changes were undertaken on each patient and at each dressing change an assessment was carried out on how the dressing had performed. The results were based on subjective data from the clinicians who took part in the evaluation.

Results

The results gained from the dressing performance were collated and analysed. Patient progress was monitored, photos and descriptions of how the wounds had progressed using ActivHeal® Hydrogel were also noted. The data was analysed and is shown in Graph 1.



Graph 1

The evaluation of the data showed that in the case of ActivHeal® Hydrogel's conformability, 71% of the responses were very satisfied and 29% were satisfied. In regards to 'maintain a moist environment', 71% were very satisfied and 29% were satisfied. The product was also assessed for ease of use, 100% were very satisfied. The overall rating of the ActivHeal® Hydrogel was 79% very satisfied and 21% satisfied. It was documented on the assessment forms that the ActivHeal® Hydrogel was effective in rehydrating the necrotic tissue and assisting in the debridement of both the necrotic and sloughy tissue. The nurses anecdotally reported that there was minimal residue left on the wound prior to the reapplication of the gel, suggesting that absorption of the product had occurred and a degree of rehydration may have been achieved. Also due to the high viscosity of the ActivHeal® Hydrogel it was also noted that there was no underlying trauma to either the surrounding skin of the wound or through maceration to the peri wound area.

Discussion

There is a lot of focus currently on driving down costs within the NHS, as clinicians it is our responsibility to ensure that if we see an opportunity to save money without compromising patient care and ensuring successful outcomes then it should be fully investigated. The ActivHeal® range offers significant savings over "branded" dressings, by switching to ActivHeal® Hydrogel savings of around 40% can be made. However cost alone is not enough justification to switch by itself, we must ensure that the dressings perform to a high enough standard and ensure that it doesn't impact negatively on the patient, or ourselves as clinicians. The case series evaluation demonstrates that the ActivHeal® Hydrogel is easy to use, conformable, and maintains a moist wound environment. The above results and

the case study demonstrate that ActivHeal® Hydrogel, is an effective wound care choice that has effectively assisted in the facilitation of autolysis and debridement of both necrotic and sloughy tissue, creating the right environment for healing. All the patients wounds within the study were effectively debrided and the devitalised tissue removed. The overall rating of 79% very satisfied and 29% satisfied with the product, supports that the product is acceptable for wounds and can enhance patient care whilst supporting the concept of a cost effective option.

Conclusion

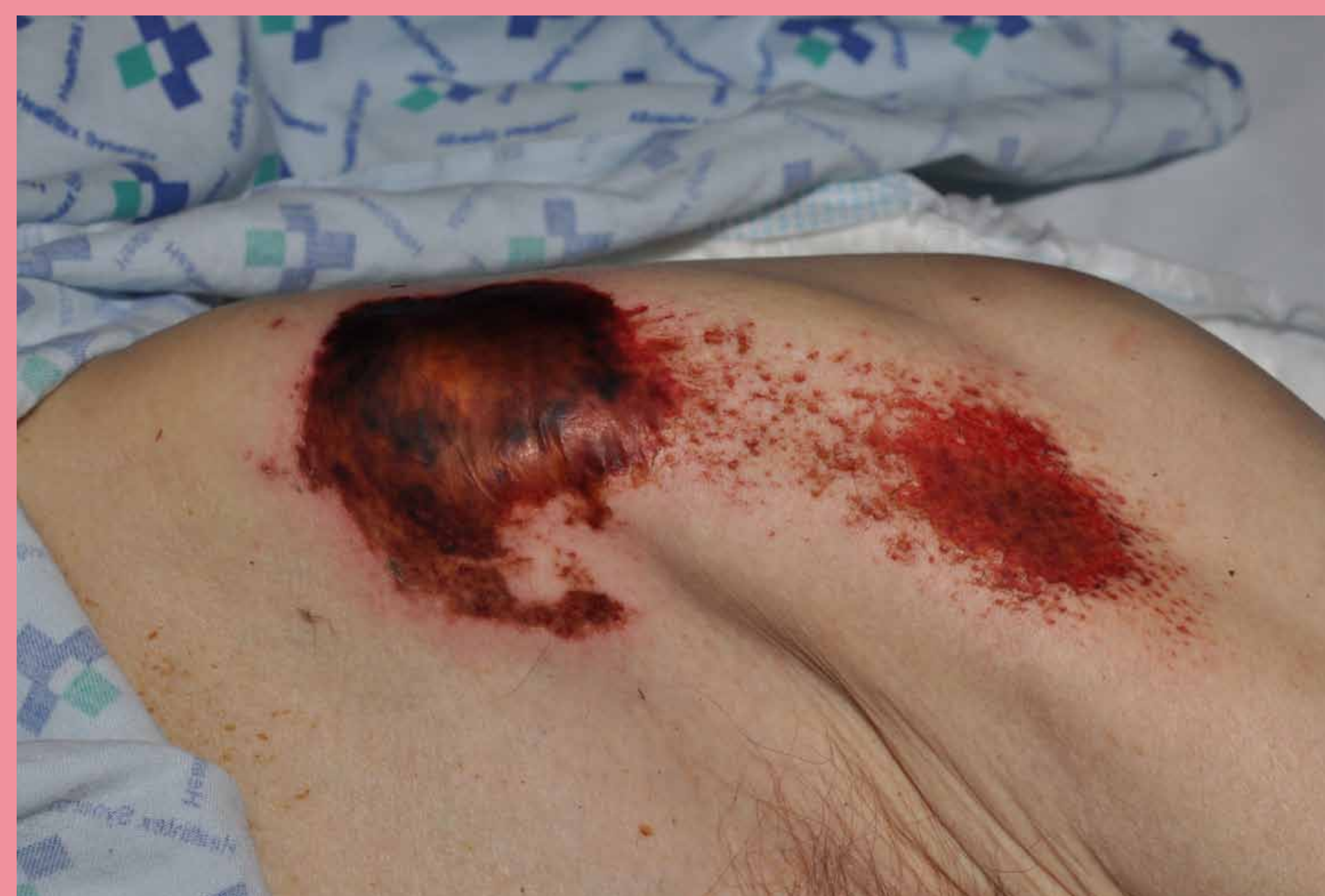The outcome of the study supports that ActivHeal® Hydrogel is effective in the rehydration and debridement of both necrotic and sloughy wounds and provides enhanced outcomes for the clinician and the patient. ActivHeal® Hydrogel is a good choice of hydrogel for trusts that are looking to save money without compromising patient care and patient outcomes.

Case study

Mrs DC was a 75 year old lady who had been found on the floor for an unknown length of time following a collapse. On admission she was assessed and was found to have 18 wounds documented. She was also dehydrated, and had a poor nutritional status. She was referred to Tissue Viability for advice.

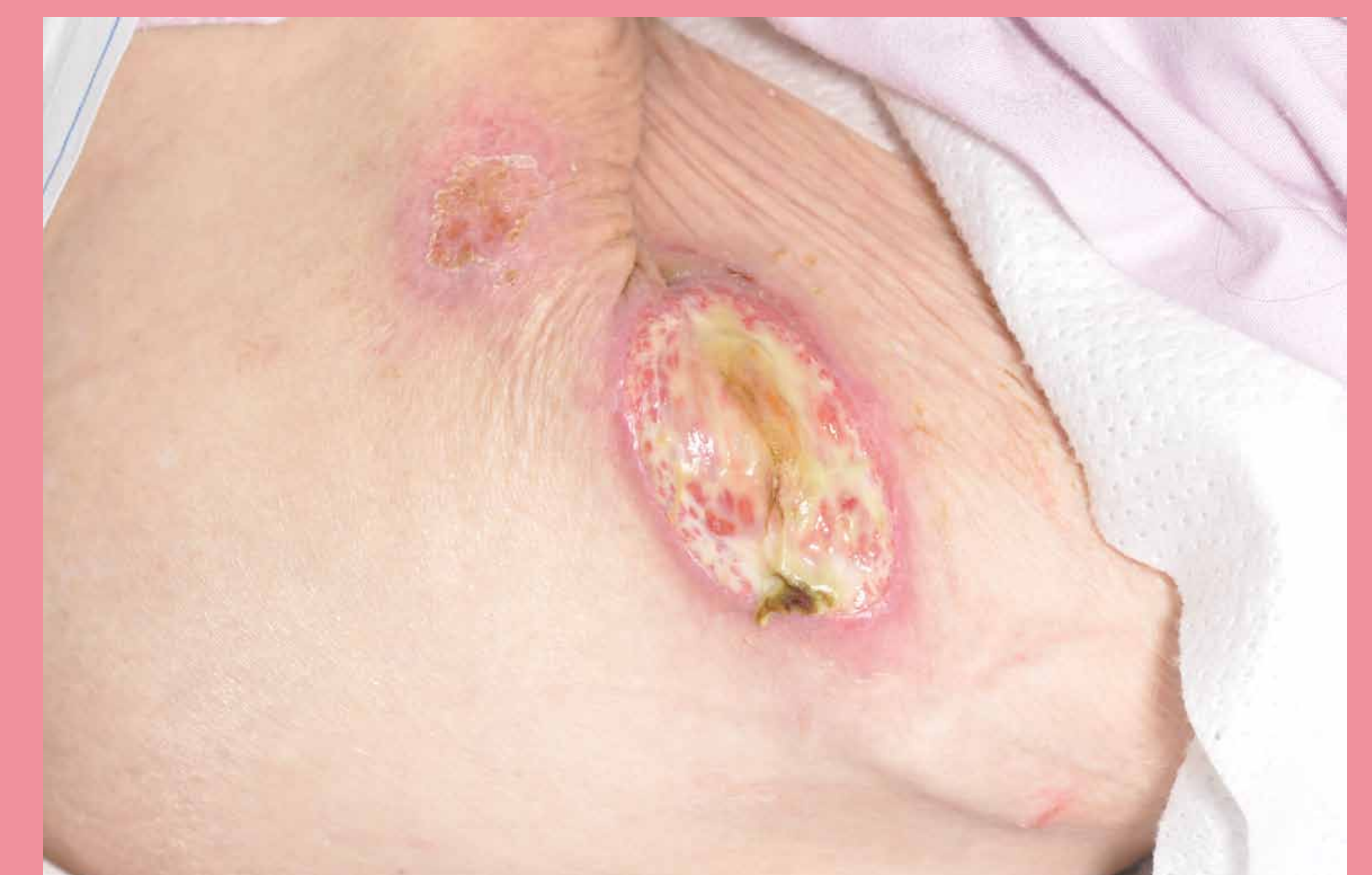Initial assessment of (Picture 1) wound presented an 8cm x 8cm necrotic wound over a bony prominence to left hip. A grade 4 pressure ulcer was diagnosed. Following initial assessment the treatment aim for the wound was to soften the necrotic tissue to enable sharp debridement, therefore ActivHeal® Hydrogel was selected.

ActivHeal® Hydrogel was applied daily for 5 days. On day 5 the eschar had softened enough to sharp debride. The wound was reassessed



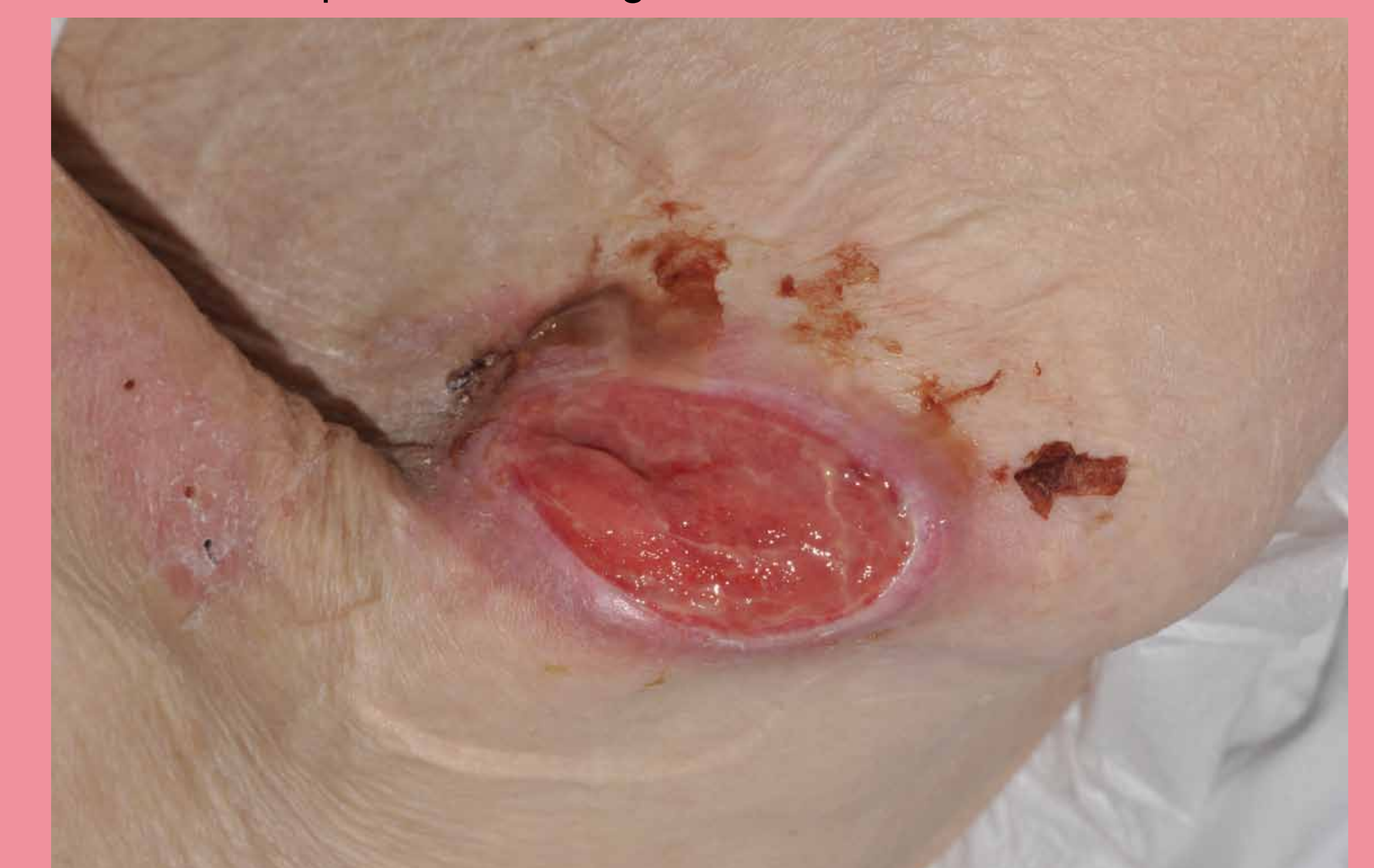Picture 1

Due to exudate levels increasing and the wound becoming quite wet, the dressing was reviewed and changed to ActivHeal Aquafiber® and ActivHeal® Foam Adhesive as the secondary dressing. The wound was covered with 70% sloughy tissue and by using ActivHeal Aquafiber® the treatment aim was to manage the levels of exudate to provide a moist wound environment and aid autolysis of the sloughy tissue. The wound was dressed daily for 4 days due to the level of exudate until day 4 when it was changed to alternate days due to a reduction in exudate.



Picture 2

By Picture 3 the wound exudate had significantly reduced therefore the dressing was changed to a non adherent contact layer and the ActivHeal® Foam Adhesive. All sloughy tissue had been removed and the wound was 100% granulating. By choosing the non adherent dressing and ActivHeal® Foam Adhesive the treatment aim was to provide a moist wound environment, whilst protecting the newly formed granulation tissue and promote healing. This wound went on to heal.



Picture 3